

# Morphometric Analysis of Age and Gender-related Variations of Corpus Callosum by using Magnetic Resonance Imaging: A Cross-sectional Study

NAVIR PASRICHA<sup>1</sup>, ETI STHAPAK<sup>2</sup>, ASHISH THAPAR<sup>3</sup>, RAJAN BHATNAGAR<sup>4</sup>

## ABSTRACT

**Introduction:** The Corpus Callosum (CC) is the largest commissural bundle connecting the two cerebral hemispheres which is involved in learning, memory, thinking, three-dimensional visual ability, executive functions as well as behavioural patterns. Exact morphometric dimensions are a prerequisite before surgical interventions and stereotactic approaches to the foramen of Munro and also in cases of callosotomy for intractable epilepsy as inconsistencies exist regarding gender and age related changes of CC. Also, most published studies are from the western world and very few studies are from South-east Asia and India.

**Aim:** To study the morphometry of CC and possible age, gender related variations using Magnetic Resonance Imaging (MRI) in the North Indian population.

**Materials and Methods:** An observational, cross-sectional study was done in Dr. Ram Manohar Lohia Institute of Medical Sciences, Lucknow, Uttar Pradesh, India from January 2019 to October 2019. A total of 200 head MRI scans, using PACS (Picture Archiving and Communication System) System Viewer software were evaluated. In all the scans, length, height, minimum and maximum thickness of CC were studied. The data were statistically analysed using

STATA Software for age and gender-related differences. Student's t-test, one-way Analysis of Variance (ANOVA), linear regression and Pearson correlation coefficient were applied.

**Results:** The study showed decrease in thickness of body, rostrum and splenium with age, linked to generalised degeneration of cortical neurons or atrophy of white matter with advancing age. Also, there was increase in length with age, possibly due to age mediated structural dilatation in lateral ventricles. Statistically significant sexual dimorphism was observed as a larger CC length in males (74.24±4.26 mm) than females (72.67±4.16 mm) (p-value <0.001) and larger brain length in males (171.75±5.51 mm) as compared to females (163.70±5.75 mm) (p-value <0.001). Males also showed greater splenial thickness (10.15±1.79 mm) in comparison to females (9.68±1.51 mm) (p-value <0.001) which may represent the importance of distribution of fibres of visual cortex in males due to larger occipital lobe.

**Conclusion:** The present study documented morphometry of normal CC in different gender and age groups and observed sexual dimorphism, especially greater CC length and splenial thickness in males than females. With age increase in the length and decrease in thickness of CC was seen.

**Keywords:** Ageing, Atrophy, Brain, Cognition, Commissural bundle

## INTRODUCTION

The morphometric analysis of physiologic variations in CC morphology is important. These variations may cause problems in diagnosis and treatment of neuropsychiatric disorders, dysmyelinating and demyelinating disorders, pre-and perinatal trauma, or hypoxic injury [1-3]. The CC forms a massive arched inter-hemispheric bridge in the floor of the median longitudinal cerebral fissure which connects cortical as well as subcortical regions of the right and left-sides of the brain and plays an essential role in the integration of information between the two hemispheres. The human CC has been divided antero-posteriorly into four main parts, including the genu, the rostrum, the body or trunk, which is frequently subdivided into anterior, middle, posterior, and the splenium. Variations in morphology of CC have been quoted in a wide range of neuropsychiatric disorders [4,5].

Neurologists and anatomists have debated and researched on morphometry of CC and the association of the variations with intelligence and comprehension. Researchers have shown that it is involved in many advanced features of the brain, such as learning, memory, thinking, three-dimensional visual ability, executive functions as well as behavioural patterns [6,7].

Interestingly, such results point out towards possible relation between morphometry of CC with the difference in cognition and behavioural pattern seen in males and females. Hence, sexual

dimorphism of CC became an emerging topic of interest among the scientific communities. Despite the earlier work done on CC and its relationship with gender, there is no unanimity in literature concerning the same. Many studies have found significant sex differences in the length, shape and area of the CC of males and females; with males having larger gross dimensions [8-12].

Such results are again reasoned with contradictory studies, one attributing the apparent callosal dimorphism to individual difference in brain size [13,14] while the other concluded that the observed results in callosal anthropometric measurements are real and would remain significant even after adjusting for the main proposed confounders, including brain size [15]. However, there are several reports where no sex related differences in the size and various other measurements of CC have been reported [16-18]. Inconsistencies also lie regarding age related changes of CC. Hence, despite rigorous investigations on gender-related variations of CC, much controversy still exists in the literature.

In surgical interventions and stereotactic approaches to the foramen of Monro or third ventricle and callosotomy for intractable epilepsy, MRI especially T1 weighted images, are required as a preoperative measure for determination of the extent of callosotomy as well as for postoperative evaluation. Past studies have taken lesser morphometric parameters, insufficient sample size or in some cases, diseased subjects without their proper medical history, which have

led to disparities in results. Also, most published studies investigated gender and age related CC variations in the western countries and few studies addressed it in any Southeast Asian country like India [18-20]. In view of the importance of the dimensions of CC, present study aimed to address these issues to study the morphometry of CC and possible age, gender-related variations using MRI in the North Indian population.

## MATERIALS AND METHODS

An observational, cross-sectional study was done in Department of Anatomy, Dr. Ram Manohar Lohia Institute of Medical Sciences, Lucknow, a Multispecialty referral Institute in Uttar Pradesh, India from January 2019 to October 2019. Prior clearance was taken from the Institutional Ethics Committee (IEC No.96/18 Date 03/05/19) and for using data from Institutional PACS System, approval with waiver of consent was accorded.

**Inclusion criteria:** Head MRI scans of 200 individuals (109 males and 91 females), aged between 20-80 years, who were referred to the institute for head MRIs and were reported to have normal images by the Radiologist, were included in the study.

**Exclusion criteria:** Scans with pathological findings like tumours, infections, trauma, hydrocephalus, demyelinating lesions, and congenital anomalies and those younger than 20 and older than 80 years were excluded from the study.

**Sample size calculation:** Since this was an Indian Council of Medical Research (ICMR) Short Term Studentship (STS) project with data collection over a period of two months, convenience sampling method was used to take a sample size of 200 subjects.

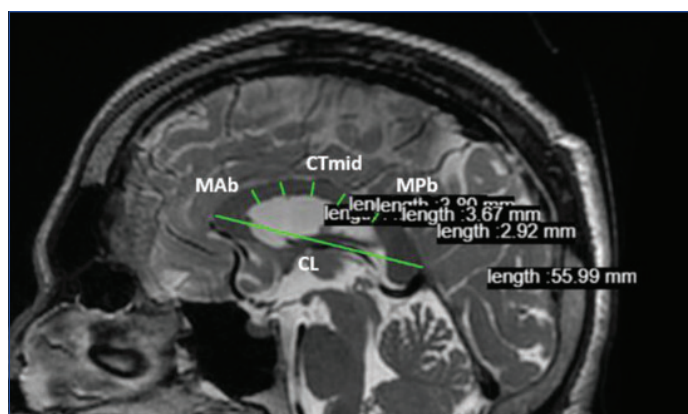
### Study Procedure

Demographic data such as age, gender were collected for all the individuals. PACS System Viewer software was used to measure and record the dimensions by a single observer. Given parameters [21] were measured with abbreviations as shown in [Table/Fig-1].

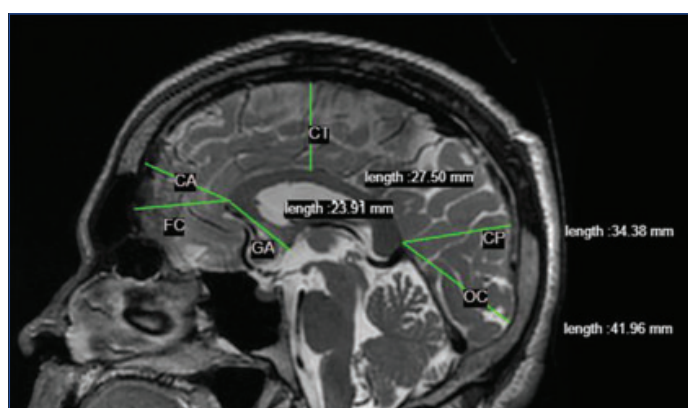
1.	BL	Brain Length; as maximum length from the occipital to the frontal pole of the cerebrum for each hemisphere-BL1 and BL2, respectively
2.	CL	Length of CC
3.	CTmid	Thickness of CC in the middle, at the centre of CC length
4.	Tr	Maximum thickness of rostrum below the genu segment
5.	Ts	Maximum thickness of splenium starting at posterior most point of CC
6.	CH	Height of CC; as the distance between a line through the inferior borders of rostrum and splenium and a line parallel to that
7.	Tbmax	Maximum thickness of the body of CC (anywhere)
8.	Tbmin	Minimum thickness of the body of CC (anywhere)
9.	MA b	Maximum thickness of the anterior part of CC excluding rostrum and genu
10.	MP b	Maximum width of the posterior part of CC excluding splenium
11.	GA	Distance between anterior most point of CC and anterior commissure
12.	CA	Shortest distance from anterior most point of CC to the cortex surface
13.	CT	Shortest distance from top most point of CC to the cortex surface
14.	CP	Shortest distance from posterior most point of CC to the cortex surface
15.	FC	Distance from frontal pole to anterior most point of CC
16.	OC	Distance from occipital pole to posterior most point of CC

[Table/Fig-1]: List of parameters of Corpus Callosum (CC) measured along with their abbreviations.

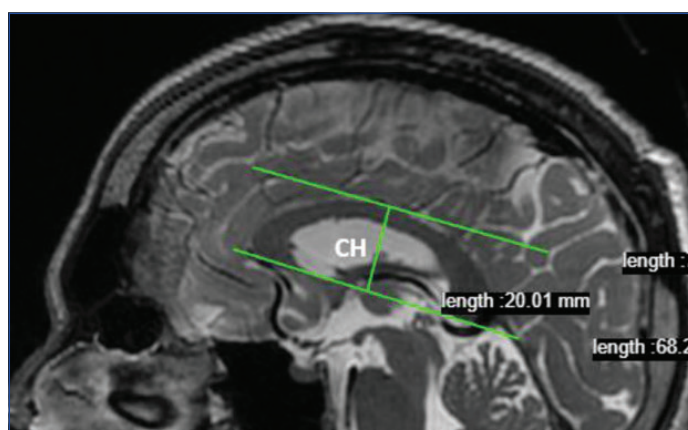
MRI images of the following are shown in [Table/Fig-2-4]. The subject scans selected were further divided into age groups of 20-39 years, 40-59 years and 60-80 years. All measurements were taken in the mid-sagittal plane using method described by Mitchell TN et al., by determining mid points of posterior and anterior commissure [22]. T1 weighted MRI images obtained from GE Healthcare 3.0T MRI scanners were manually studied on the SYNAPSE PACS viewer software available with the institute.



[Table/Fig-2]: MRI image showing various morphometric dimensions taken. CL is the length of corpus callosum. MA b measured maximum thickness of the anterior part of corpus callosum excluding rostrum and genu; CT mid measurement of thickness of CC in the middle, at the centre of CC length; MP b measured the maximum width of the posterior part of corpus callosum excluding splenium.



[Table/Fig-3]: MRI image showing various morphometric dimensions taken with respect to corpus callosum and brain dimensions. FC is the distance from frontal pole to anterior most point of CC; CA is the shortest distance from anterior most point of CC to the cortex surface; GA is the distance between anterior most point of CC and anterior commissure; CP is the shortest distance from posterior most point of CC to the cortex surface; OC is the distance from occipital pole to posterior most point of CC; CT is the shortest distance from top most point of CC to the cortex surface.



[Table/Fig-4]: MRI image showing height of corpus callosum taken. Measurements taken in mm.

## STATISTICAL ANALYSIS

The data were statistically analysed for age and gender-related differences and checked for correlation by STATA Software (STATA Inc.). Student's t-test, one-way ANOVA, linear regression and Pearson correlation coefficient were used to analyse the data. The p-value <0.05 were considered significant.

## RESULTS

The study analysed MRI scans of 200 subjects (109 males and 91 females) with mean age 49.05±19.7 years, ranging from 20-80 years. The average CC length (CL) was found to be 73.53±4.28 mm (95% CI-62.92-82.53), while CC thickness at midpoint (CT mid)

was 4.41±1.08 mm (95% CI-2.28-6.59) and CC height (CH) was 24.87±2.86 mm (95% CI-19.4-32.59) [Table/Fig-5].

Measurement	Mean±SD (mm)	Range
BL 1	168.09±6.90	153.18-183.55
BL 2	167.59±7.11	152.53-185.6
CL	73.53±4.28	62.92-82.53
CT mid	4.41±1.08	2.28-6.59
Tr	5.96±1.16	3.77-8.86
Ts	9.94±1.68	6.13-13.5
CH	24.87±2.86	19.4-32.59
Tb max	5.16±1.03	3.05-7.55
Tb min	3.49±0.87	1.98-5.47
MA b	4.54±0.97	2.43-7.26
MP b	4.41±1.02	2.16-7.72
GA	30.63±2.30	21.98-37.68
CA	35.17±3.19	23.79-43.03
CT	36.58±3.46	27.54-47.8
CP	44.40±3.64	34.44-52.17
FC	37.08±3.02	28.71-44.39
OC	56.87±6.14	42.93-78.49

**[Table/Fig-5]:** The dimensions of the various parameters, their SD and range within 95% confidence limits.

The study observed statistically significant sexual dimorphism with a larger CC Length (CL) and Brain length (BL1, BL2) in males as compared to females. The difference in CC length and Splenial thickness (Ts) among males and females was statistically significant. The mean value of Tbmax, MP b, MA b and GA were also higher among males but the difference was not found significant [Table/Fig-6].

Measurement	Males (N=109) Mean±SD (mm)	Females (N=91) Mean±SD (mm)	Difference (95% CI)	p-value
BL 1	171.75±5.51	163.70±5.75	8.06 (6.48,9.63)	<0.001
BL 2	171.50±5.50	162.92±5.91	8.57 (6.98,10.17)	<0.001
CL	74.24±4.26	72.67±4.16	1.57 (0.39,2.75)	<0.001
CT mid	4.40±1.06	4.43±1.10	-0.03 (-0.33,0.27)	0.846
Tr	5.91±1.24	6.03±1.05	-0.12 (-0.44,0.20)	0.457
Ts	10.15±1.79	9.68±1.51	0.47 (0.01,0.94)	<0.001
CH	24.55±2.78	25.26±2.92	0.47 (0.01,0.94)	0.082
Tb max	5.26±1.05	5.04±1.01	0.22 (-0.07,0.51)	0.137
Tb min	3.48±0.87	3.49±0.87	0.00 (-0.25,0.24)	0.979
MA b	4.63±0.91	4.43±1.03	0.00 (-0.25,0.24)	0.136
MP b	4.45±1.07	4.35±0.95	0.10 (-0.19,0.38)	0.490
GA	30.92±2.20	30.29±2.38	0.62 (-0.02,1.26)	0.057
CA	35.83±3.06	34.37±3.18	1.46 (0.59,2.34)	0.001
CT	36.77±2.71	36.35±4.20	1.46 (0.59,2.34)	0.390
CP	45.51±3.27	43.07±3.64	2.44 (1.48,3.41)	<0.001
FC	37.76±2.64	36.26±3.25	1.50 (0.68,2.32)	<0.001
OC	59.21±5.19	54.06±6.02	5.15 (3.59,6.71)	<0.001

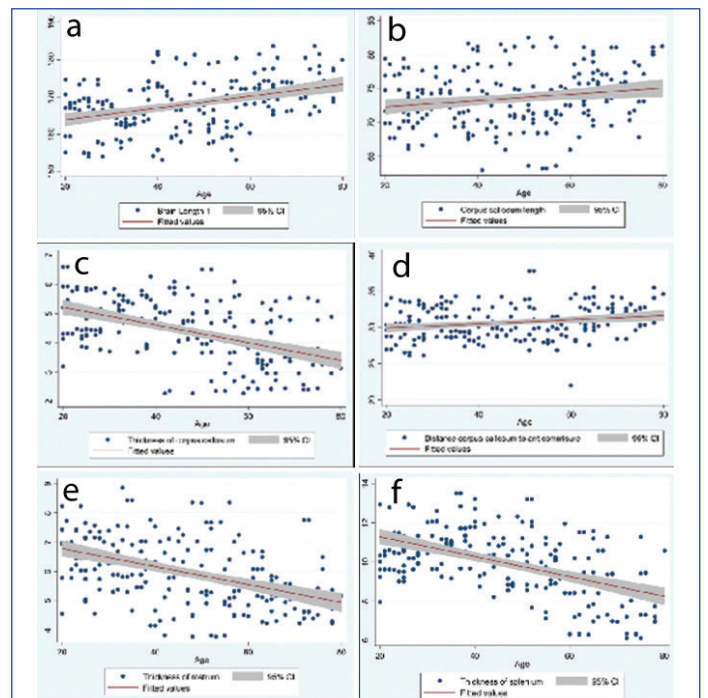
**[Table/Fig-6]:** The comparison of morphometric values of CC among males and females. unpaired student t-test

In present study, it was observed that there was decrease in thickness of Body (CTmid), Rostrum (Tr) and Splenium (Ts) with age which may be linked to generalised degeneration of cortical neurons or atrophy of white matter with advancing age. Present study also observed increase in length of CC (CL) with age, possibly due to age mediated structural dilatation in lateral ventricles and its association with CC [Table/Fig-7].

Linear correlation between morphometric brain measurements and age measured over a continuous scale is depicted in [Table/Fig-8,9].

Variables	20-39 years (Mean±SD) N=80 (mm)	40-59 years (Mean±SD) N=64 (mm)	60-79 years (Mean±SD) N=56 (mm)	p-value
BL 1	165.46±5.73	167.32±7.69	172.73±4.97	<0.001
BL 2	165.45±6.37	166.83±7.58	171.53±5.95	<0.001
CL	73.02±3.60	72.60±4.99	75.31±3.80	<0.001
CT mid	4.94±0.75	4.43±1.14	3.64±0.94	<0.001
Tr	6.54±0.98	5.84±1.26	5.28±0.82	<0.001
Ts	10.73±1.14	10.24±1.47	8.45±1.62	<0.001
CH	24.43±2.78	24.95±2.45	25.41±3.31	0.143
Tb max	5.72±0.76	5.12±0.95	4.39±0.97	<0.001
Tb min	3.87±0.71	3.45±1.02	2.99±0.60	<0.001
MA b	5.07±0.64	4.57±0.96	3.75±0.83	<0.001
MP b	4.88±0.93	4.37±0.92	3.77±0.88	<0.001
GA	30.31±2.14	30.22±2.27	31.56±2.33	<0.001
CA	34.97±3.26	34.28±3.04	36.46±2.90	<0.001
CT	37.11±2.30	36.25±4.00	36.20±4.10	0.208
CP	44.34±3.13	44.00±3.94	44.95±3.95	0.358
FC	37.28±2.90	36.25±2.82	37.72±3.25	0.021
OC	56.82±4.88	55.89±6.56	58.06±7.08	0.154

**[Table/Fig-7]:** The age-related differences and variations with age in three different age groups. ANOVA test



**[Table/Fig-8a-f]:** The relationship of dimensions of CC with age (p-value <0.05). Linear correlation has been depicted by calculating Pearson-correlation (r). (a) Variation of brain length with age. (r=0.39); (b) Variation of CC length with age. (r=0.18); (c) Variation of thickness of body of CC with age (r=-0.48); (d) Variation of distance between anterior most point of CC and anterior commissure with age (r=0.21); (e) Variation of thickness of rostrum with age (r=-0.45); (f) Variation of thickness of splenium with age (r=-0.52).

Variables	Pearson correlation (r)	p-value	Variables	Pearson correlation (r)	p-value
BL	0.39	<0.001	MA b	-0.54	<0.001
CL	0.18	0.010	MP b	-0.43	<0.001
CT mid	-0.48	<0.001	GA	0.21	0.002
Tr	-0.45	<0.001	CA	0.18	0.01
Ts	-0.52	<0.001	CT	-0.09	0.205
CH	0.12	0.09	CP	0.06	0.398
Tb max	-0.49	<0.001	FC	0.05	0.482
Tb min	-0.41	<0.001	OC	0.07	0.326

**[Table/Fig-9]:** Pearson correlation of various parameters of brain with age.

Morphometric brain measurements Tr, Ts, Tb max, Tb min, MA b, MP b had statistically significant ( $p < 0.001$ ) negative correlation with age; while CT had a non significant negative correlation. Morphometric brain measurements BL, CL, CA, GA had a statistically significant positive correlation with age; while CH, CP, FC, OC had a non significant positive correlation with age.

[Table/Fig-10] depicts the unadjusted and gender adjusted coefficient obtained by linear regression of morphometric brain measurements with age. BL, shows the highest increase with increasing age (0.157 mm with each year increase in age) and Ts shows the maximum decrease with increasing age (-0.051 mm with each year increase in age). The gender adjustment of coefficient did not have any effect over the statistical significance.

Variables	Unadjusted $\beta$ coefficient	p-value	Gender adjusted $\beta$ coefficient	p-value
BL 1	0.157	<0.001	0.155	<0.001
BL 2	0.128	<0.001	0.126	<0.001
CL	0.046	0.009	0.045	0.009
CTmid	-0.030	<0.001	-0.030	<0.001
Tr	-0.031	<0.001	-0.031	<0.001
Ts	-0.051	<0.001	-0.051	<0.001
CH	0.020	0.087	0.020	0.082
Tb max	-0.030	<0.001	-0.030	<0.001
Tb min	-0.021	<0.001	-0.021	<0.001
MA b	-0.030	<0.001	-0.030	<0.001
MP b	-0.026	<0.001	-0.026	<0.001
GA	0.028	0.003	0.028	0.003
CA	0.032	0.013	0.032	0.012
CT	-0.018	0.223	-0.018	0.221
CP	0.012	0.424	0.011	0.422
FC	0.009	0.458	0.009	0.464
OC	0.026	0.312	0.024	0.292

[Table/Fig-10]: Linear regression values of various dimensions of CC with age.

## DISCUSSION

Normal shape, size and topographic location of CC has been well worked upon by researchers like Anagnostopoulou S et al., and these studies have been mostly done on formalin fixed preserved brains [17]. Only a few MRI studies [23-26] have been documented to study normal morphometry in different populations as shown in [Table/Fig-11].

Investigations of sex differences in CC size have yielded mixed results. One of the initial studies to document sexual dimorphism was conducted by Bean RB in American population who suggested that “exceptional size of the CC may mean exceptional intellectual activity” to account for measurable differences between men and women [18]. DeLacoste-Utamsing C and Holloway RL concluded by measurements of cross-sectional area of CC in 14 postmortem brains (5 females and 9 males) that on an average, “relative to brain size,” the CC mid-sagittal area (CCA) in females may be larger than in males [8]. Their results were reviewed in another autopsy data which also stated that “splenium, posterior section of CC, is more bulbous in women than men” [10].

Oka S et al., from a study in Japanese population also supported by correlating callosal morphometry with dimorphism of brain length for

both the genders [27]. Contrarily, reviews done by George BA et al., and Bishop KM and Wahlsten D concluded that there is no evidence suggesting a significant sex difference in the size of the CC at all [28,29]. A recent study by Abdolmaleki A et al., in Iranian population found apparently larger callosal dimensions in male participants but also provided evidence regarding the confounding effect of brain volume on the observed sexual dimorphism [15]. Hence, a concluding perspective for the given variations could be that “smaller brains may have relatively larger CC regardless of gender” and since average brain size in females is smaller than in males, the observations may be accounted for by comparison of groups with different average brain sizes and not due to gender. Studies done by Peter M and Jäncke L et al., in German population, McLeod NA et al., in American population, Bermudez P and Zatorre RJ in Canadian population and Bruner E et al., on Spanish population, justify that any observed difference between groups is not gender specific but may be due to differences in brain size [30-34]. Study by Tepest R et al., has employed a variety of methodologies for measurement and normalisation due to confounding factors but have yielded disparate results [35].

The present study observed statistically significant sexual dimorphism with a larger CC length and brain length in males as compared to females. A longer CC in males is also reported earlier in the following studies [16,17,36-42]. However, even after adjusting for brain length using covariate, regression and ratio analysis on a subset of men and women with matched intracranial size, Sullivan EV et al., in American population observed larger size of CC in male subjects [40]. Hence, this information could not be a simple artefact and might have biological significance regarding the connectivity differences in male and female brains. The present study also found that females had lesser thickness of splenium as compared to males, which may be accounted for by the fact that in males, the occipital lobe is larger with more number of fibres from visual cortex contributing to a thicker splenium in males. Previous studies try to conclude greater splenial width in females but fall short of evidence to support the presence of sex related differences in size of splenium, either in absolute size or irrespective of difference in the overall brain size in two sexes [8-11,29]. This result was also in contrast to the findings where no such gender related difference in splenium was found in Indian studies [19,20,39]. Other than this CA, CP, FC and OC were found to be greater in males signifying their greater brain size. Studies done by Peters M, Smith RJ and Byne W et al., have noted considerable variation in size and shape of CC among individuals and have advocated using a large sample size to demonstrate a significant gender difference which has been addressed in the present study [30,36,41].

Takeda S et al., worked on determination of indices of CC associated with normal ageing in Japanese individuals [37]. Similar study by Gupta E et al., found chronological decrease in width of genu and rostrum in Indian females specifically [38]. The result of length and width of CC of present study are comparable with findings from other population [8-12] and in concordance with Indian studies [19,20], that is decrease in thickness of body, rostrum and splenium with age linked to generalised degeneration of cortical neurons or atrophy of white matter with advancing age. Also, contrary to general belief that CC shrinks with age this study found an increase in length of CC with age, possibly due to age mediated structural dilatation in lateral ventricles. As depicted in [Table/Fig-12], this finding was

S. No.	Author, publication year, place	Sample size	Mean/Median age (years)	Brain length (mm)	CC length (mm)	CC height (mm)	CC body thickness (mm)	Splenium thickness (mm)
1.	Present study, 2023 (India)	200	49.05±19.7	167.12±7.62	73.53±4.28	24.87±2.86	5.16±1.03	9.94±1.68
2.	Chuks A et al., 2023 (Nigeria) [23]	200	43.57±19.02	159.37±6.1	75.94±4.9	24.77±4.0	5.64±1.4	11.01±1.7
3.	Allouh MZ et al., 2020 (Jordan) [24]	100	20-45	157.4±6.55	68.45±4.1	-	6.15±0.8	16.65±2.4
4.	Arda KN and Akay S, 2019 (Turkey) [25]	436	47.05±19.8	-	68.0±4.9	24.7±3.1	5.81±1.1	13.6±0.9
5.	Junle Y et al., 2008 (China) [26]	286	40-49	-	70.74±4.4	24.59±2.7	6.33±0.9	11.53±1.3

[Table/Fig-11]: Racial comparison of the morphometric measurements of the Corpus Callosum (CC) within different ethnic backgrounds [23-26].

S. No.	Author	Sample size	Population	Publication year	Pearson's coefficient						
					CC length	CC height	Body width at mid point	Splenium width	Rostrum width	Body width anteriorly	Body width posteriorly
1.	Present study	200	North Indian	2023	0.18	0.12	-0.48	-0.52	-0.45	-0.54	-0.43
2.	Arda KN and Akay S, [25]	436	Turkish	2019	0.11	0.07	-	-0.11	-	-0.31	-0.19
3.	Chuks A et al., [23]	200	Nigerians	2023	0.22	0.25	-0.14	-0.21	-0.10	-	-
4.	Suganthy J et al., [20]	100	South Indian	2003	0.28	-	-0.21	-0.44	-	-	-

**[Table/Fig-12]:** Comparison of Pearson's coefficient for age related morphometric changes of the Corpus Callosum (CC) within different ethnic backgrounds [20,23,25].

comparable with result of many studies on this topic [20,23,25] but was in contrast with studies which justify decreases in CC length simultaneously [42,43]. Present study found increase in height of CC as reported by Takeda S et al., [37].

On adjusting for gender, value of beta coefficient for callosal length decreases, which signifies that age related changes are more rapid in males than females causing earlier decline in dichotic listening and binaural processing skill in males, which is also suggested by Witelson SF and Cowell PE et al., [12,43]. Except the decrease in CC length, seen more significantly in males with ageing, the present study did not find any sexual difference in the pattern of ageing of CC.

### Limitation(s)

Present study was a cross-sectional study without any direct comparison between subjects. Ideally, a longitudinal study over several decades should be performed, comparing change in morphometry with age in the same subjects.

### CONCLUSION(S)

On analysing the morphometry of normal CC, sexual dimorphism, especially greater CC length and splenial thickness was observed in males than females. In changes with respect to age, the study found increase in the length and decrease in thickness of CC in the older age group. Significant decrease in thickness of body, rostrum and splenium with age was observed which could be linked to generalised degeneration of cortical neurons or atrophy of white matter with advancing age. The morphometric data obtained from present study can aid the clinicians with diagnosis of presence and progression of disease involving the CC.

### REFERENCES

- Walterfang M, Velakoulis D. Callosal morphology in schizophrenia: What can shape tell us about function and illness? *Br J Psychiatry*. 2014;204:09-11. Doi: 10.1192/bjp.bp.113.132357.
- Bachman AH, Lee SH, Sidtis JJ, Ardekani BA. Corpus callosum shape and size changes in early Alzheimer's disease: A longitudinal MRI study using the OASIS brain database. *J Alzheimers Dis*. 2014;39:71-78. Doi: 10.3233/JAD-131526.
- Hutchinson AD, Mathias JL, Banich MT. Corpus callosum morphology in children and adolescents with attention deficit hyperactivity disorder: A meta-analytic review. *Neuropsychology*. 2008;22:341-49. Doi: 10.1037/08944105.22.3.341.
- Duff BJ, Macritchie KA, Moorhead TW. Human brain imaging studies of DISC1 in schizophrenia, bipolar disorder and depression: A systematic review. *Schizophr Res*. 2013;147:1-13. Doi: 10.1016/j.schres.2013.03.015.
- Bellani M, Calderoni S, Muratori F, Brambilla P. Brain anatomy of autism spectrum disorders I. Focus on corpus callosum. *Epidemiol Psychiatr Sci*. 2013;22:217-21. Doi: 10.1017/s2045796013000139.
- Verger K, Junque C, Levin HS. Correlation of atrophy measures on MRI with neuropsychological sequelae in children and adolescents with traumatic brain injury. *Brain Inj*. 2001;15:211-21. Doi: 10.1080/02699050010004059.
- Caille S, Sauerwein HC, Schiavetto A. Sensory and motor interhemispheric integration after section of different portions of the anterior corpus callosum in nonepileptic patients. *Neurosurgery*. 2005;57:50-59.
- DeLacoste-Utamsing C, Holloway RL. Sexual dimorphism in the human corpus callosum. *Science*. 1982;216:1431-32. Doi: 10.1126/science.7089533.
- Allen LS, Richey MF, Chai YM, Gorski RA. Sex differences in the corpus callosum of the living human being. *J Neurosci*. 1991;11:933-42.
- Holloway RL, Anderson PJ, Defendini R, Harper C. Sexual dimorphism of the human corpus callosum from three independent samples: Relative size of the corpus callosum. *Am J Phys Anthropol*. 1993;92:481-98.
- Davatzikos C, Resnick SM. Sex difference in anatomic measures of interhemispheric connectivity: Correlations with cognition in women but not men. *Cereb Cortex*. 1998;8:635-40.
- Witelson SF. Hand and sex differences in the isthmus and genu of the human corpus callosum. A postmortem morphological study. *Brain*. 1989;112:799-835.
- Luders E, Toga AW, Thompson PM. Why size matters: Differences in brain volume account for apparent sex differences in callosal anatomy: The sexual dimorphism of the corpus callosum. *Neuroimage*. 2014;84:820-24. Doi: 10.1016/j.neuroimage.2013.09.040.
- Luders E, Narr KL, Zaidel E. Gender effects on callosal thickness in scaled and unscaled space. *Neuroreport*. 2006;17:1103-06.
- Abdolmaleki A, Mastery Farahani R, Ghoreishi SK. Magnetic resonance imaging-based morphometric assessment of sexual dimorphism of corpus callosum. *Anatomical Sciences*. 2016; 13:117-24.
- Going JJ, Dixon A. Morphometry of the adult human corpus callosum: Lack of sexual dimorphism. *J Anat*. 1990;171:163-67.
- Anagnostopoulou S, Mourgela S, Katritsis D. Morphometry of corpus callosum: An anatomical study. *Neuroanatomy*. 2006;5:20-23.
- Bean RB. Some racial peculiarities of the Negro brain. *Am J Anat*. 1906;5:353-432. Doi: 10.1002/aja.1000050402.
- Putthanveetil A, Balan RK. Morphometric analysis of corpus callosum-A study in cadaver and MRI. *J Evid Based Med Healthc*. 2017;4:3219-22. Doi: 10.18410/jebmh/2017/639.
- Suganthy J, Raghuram L, Antonisamy B. Gender-and age-related differences in the morphology of the corpus callosum. *Clin Anat*. 2003;16:396-403. Doi: 10.1002/ca.10161.
- Gupta T, Singh B, Kapoor K, Gupta M, Kochhar K. Age and sex related variations in corpus callosal morphology. *Nepal Med Coll J*. 2008;10(4):215-21.
- Mitchell TN, Free SL, Merschhemke M. Reliable callosal measurement: Population normative data confirm sex-related differences. *Am J Neuroradiol*. 2003;24:410-18. Doi: 10.1086/427117.
- Chuks A, Chukwuebuka CF, Mgbe EK, Efekemo AO, Onuh AO, Nnamani A, et al. MRI-based morphometric analysis of corpus callosum dimensions of adults in Southeast Nigeria. *Libyan Journal of Medicine*. 2023;18:1. Doi: 10.1080/19932820.2023.2188649.
- Allouh MZ, Al Barbarawi MM, Ali HA, Mustafa AG, Alomari SO. Morphometric analysis of the corpus callosum according to age and sex in Middle Eastern Arabs: Racial comparisons and clinical correlations to autism spectrum disorder. *Front Syst Neurosci*. 2020;14:30. Doi: 10.3389/fnsys.2020.00030.
- Arda KN, Akay S. The relationship between corpus callosum morphometric measurements and age/gender characteristics: A comprehensive MRI study. *J Clin Imaging Sci*. 2019;9(33):01-07.
- Junle Y, Youmin G, Yanjun G. A MRI quantitative study of corpus callosum in normal adults. *J Med Coll PLA*. 2008;23(6):346-51.
- Oka S, Miyamoto O, Janjua NA. Re-evaluation of sexual dimorphism in human corpus callosum. *Neuroreport*. 1999;10:937-40. Doi: 10.1097/00001756-199904060-00008.
- George BA, Hesselink JR, Jernigan TL. MR imaging of the corpus callosum. *AJR*. 1993;160:949-55. Doi: 10.2214/ajr.160.5.8470609.
- Bishop KM, Wahlsten D. Sex differences in the human corpus callosum: Myth or reality? *Neurosci Biobehav Rev*. 1997;21:581-601. Doi: 10.1016/s0149-7634(96)00049-8.
- Peters M. The size of the corpus callosum in males and females: Implications of a lack of allometry. *Can J Psychol*. 1988;42:313-24. Doi: 10.1037/h0084195.
- Jäncke L, Staiger JF, Schlaug G, Huang Y, Steinmetz H. The relationship between corpus callosum size and forebrain volume. *Cereb Cortex*. 1997;7:48-56. Doi: 10.1093/cercor/7.1.48.
- McLeod NA, Williams JP, Machen B, Lum GB. Normal and abnormal morphology of the corpus callosum. *Neurology*. 1987;37:1240-42. Doi: 10.1212/wnl.37.7.1240.
- Bernandez P, Zatorre RJ. Sexual dimorphism in the corpus callosum: Methodological considerations in MRI morphometry. *Neuroimage*. 2001;13:1121-30. Doi: 10.1006/nimg.2001.0772.
- Bruner E, de la Cuetara JM, Colom R, Martin-Loeches M. Gender-based differences in the shape of the human corpus callosum are associated with allometric variations. *J Anat*. 2012;220:417-21. Doi: 10.1111/j.1469-7580.2012.01476.x.
- Tepest R, Jacobi E, Gawronski A. Corpus callosum size in adults with high-functioning autism and the relevance of gender. *Psychiatry Res: Neuroimaging*. 2010;183:38-43. Doi: 10.1016/j.psychres.2010.04.007.
- Smith RJ. Relative size versus controlling for size: interpretation of ratios in research on sexual dimorphism in the human corpus callosum. *Curr Anthropol*. 2005;46:249-73.
- Takeda S, Hirashima Y, Ikeda H. Determination of indices of the corpus callosum associated with normal aging in Japanese individuals. *Neuroradiology*. 2003;45:513. Doi: 10.1007/s00234-003-1019-8.
- Gupta E, Lalwani R, Babu C, Aneja S. Age related changes of corpus callosum by MRI in females. *The Internet J of Neurology*. 2009;13:01-05. Doi: 10.5580/18a1.
- Banka S, Jit I. Sexual dimorphism in the size of the corpus callosum. *J Anat Soc India*. 1996;45:77-85.

- [40] Sullivan EV, Rosenbloom MJ, Desmond JE, Pfefferbaum A. Sex differences in corpus callosum size: Relationship to age and intracranial size. *Neurobiology of Aging*. 2001;22:603-11. Doi: 10.1016/s0197-4580(01)00232-9.
- [41] Byne W, Bleier R, Houston L. Variations in human corpus callosum do not predict gender: A study using magnetic resonance imaging. *Behav Neurosci*. 1988;102:222-27. Doi: 10.1037/0735-7044.102.2.222.
- [42] Hopper KD, Patel S, Cann TS. The relationship of age, gender, handedness and sidedness to the size of the corpus callosum. *Acad Radiol*. 1994;1:243-48. Doi: 10.1016/s1076-6332(05)80723-8.
- [43] Cowell PE, Allen LS, Zalatimo NS, Denenberg VH: A developmental study of sex and age interactions in the human corpus callosum. *Dev Brain Res*. 1992;66:187-92. Doi: 10.1016/0165-3806(92)90079-c.

**PARTICULARS OF CONTRIBUTORS:**

1. Additional Professor, Department of Anatomy, Dr. RML Institute of Medical Sciences, Lucknow, Uttar Pradesh, India.
2. Associate Professor, Department of Anatomy, Dr. RML Institute of Medical Sciences, Lucknow, Uttar Pradesh, India.
3. MBBS Student, Dr. RML Institute of Medical Sciences, Lucknow, Uttar Pradesh, India.
4. Professor and Head, Department of Anatomy, Dr. RML Institute of Medical Sciences, Lucknow, Uttar Pradesh, India.

**NAME, ADDRESS, E-MAIL ID OF THE CORRESPONDING AUTHOR:**

Dr. Navbir Pasricha,  
705, Faculty Apartments, Dr. RMLIMS, Vibhuti Khand, Gomti Nagar, Next to Indian Oil Building, Lucknow-226010, Uttar Pradesh, India.  
E-mail: nivibedi@gmail.com

**PLAGIARISM CHECKING METHODS:** [Jain H et al.]

- Plagiarism X-checker: Feb 22, 2023
- Manual Googling: Apr 22, 2023
- iThenticate Software: May 18, 2023 (17%)

**ETYMOLOGY:** Author Origin**EMENDATIONS:** 10**AUTHOR DECLARATION:**

- Financial or Other Competing Interests: This project was done as an awarded Indian Council of Medical Research Short Term Student Fellowship Presentation at a meeting: The project was presented at the 5<sup>th</sup> International Conference of Brain and Spine (held online due to the COVID-19 pandemic) held from 27<sup>th</sup>-28<sup>th</sup> July 2020.
- Was Ethics Committee Approval obtained for this study? Yes
- Was informed consent obtained from the subjects involved in the study? No
- For any images presented appropriate consent has been obtained from the subjects. No

Date of Submission: **Feb 17, 2023**Date of Peer Review: **Apr 05, 2023**Date of Acceptance: **May 27, 2023**Date of Publishing: **Jun 01, 2023**